

PRISON HEALTHCARE IN IMAGES

Chronic back pain that turned out to be tuberculous Spondylitis

J Español¹, E Ragner¹, R Albertos², RA Guerrero²

¹ Hospital Consorci Sanitari de Terrassa, ² Servicios sanitarios Centros Penitenciarios

Text received: 04-06-2014

Text accepted: 06-06-2014

INTRODUCTION

Pott disease, first described in 1779, is the most common granulomatous disease of the spine although it is rarely found in our country. It is a chronic and slowly progressive condition which always entails the dissemination of the disease from another site, even when this remains unknown. The diagnosis of this disease is established by the presence of *Mycobacterium tuberculosis* or granuloma in one or more vertebrae. Surgery is usually required for presentations on the thoracic region, discitis and evolved forms of the disease.

CLINICAL DESCRIPTION

This case involves a 37 year old male from Mali with no history of substance abuse who entered prison after the realization of a recent gastrostomy for the extraction of several foreign bodies (Body Packer). Serological testing for HIV and HCV and the tuberculin test were all negative. He didn't have a history of any other diseases except for the presence of long-term pain located in the rib cage and in the right shoulder, which he attributed to a fall from a tree that he had as a young man and which received no medical assistance.

During his stay in prison he alternated between asymptomatic periods and episodes of thoracic pain which required pharmacological and physiotherapeutic measures. It was also observed that he presented a minimal scoliotic attitude of the low thoracic and lumbar region as well as a 6mm balance of the pelvis L>R especially during the realization of different tasks in the workshop.

In spite of the use of analgesic drugs and rehabilitation, the pain became progressively more intense

until June 2013, two years after his imprisonment, when he developed a walking impairment involving lower limb weakness and numbness, with no involvement of sphincters. He was then admitted to the prison hospital, where radiological, CT and MRI examinations (see Figures 1 and 2) concluded suggestive signs of spondylitis and discitis in T8-T9 together with the complete collapse of the body of T8 and adjacent spreading with partial destruction of the body of T9. This was especially clear as for the destruction of spongy bone which involved an important infectious-inflammatory component which looked like paravertebral abscesses with anterior epidural extension causing a significant spinal stenosis which involved the compression and impaired functioning of the spinal cord.

Decompression was then approached by means of laminectomy of T8 with surgical debridement of osteomyelitis at T8-T9. Instrumented fusion of T6-T7 to T10-T11 was then conducted with polyaxial screws according to the Proliant (Exactech) operating technique (see Figures 3 and 4). All tests for mycobacteria were negative. The biopsy of vertebral bodies presented necrotizing granulomatous infiltration with multinucleated giant cells. Only one of the multiple cultures turned positive for *Staphylococcus epidermidis* and only one out of several samples presented some colonies of *Corynebacterium spp.*

Since histological findings and the clinical background suggested tuberculous spondylitis, a 4-drug anti-TB treatment was initiated (rifampicin, isoniazid, pyrazinamide and ethambutol) together with an anti-staphylococcal antibiotic (levofloxacin).

The patient has evolved favorably ever since, with an improved control of his back pain and an improved function of his lower limbs with rehabilitation physiotherapy.

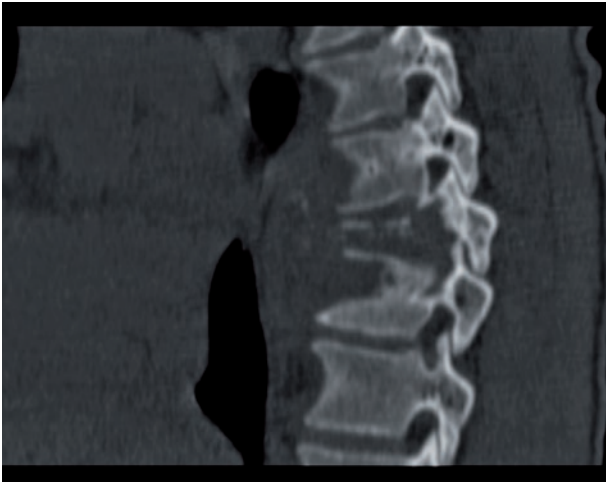


Figure 1.

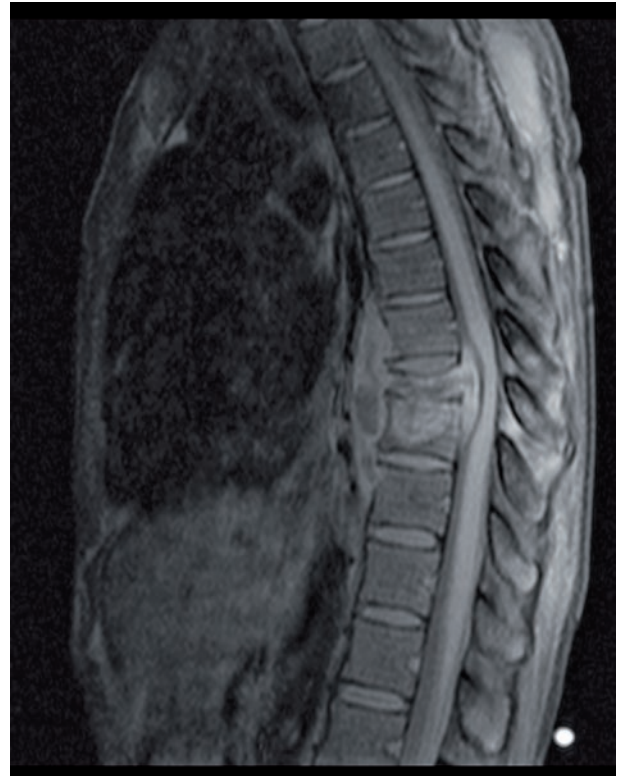

Figure 2.

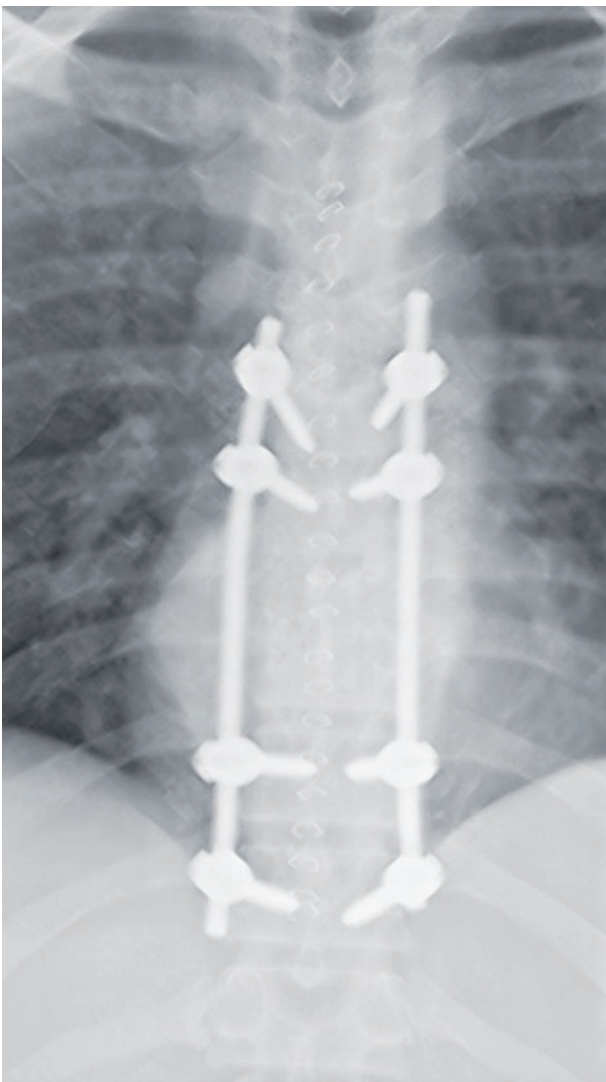


Figure 3.

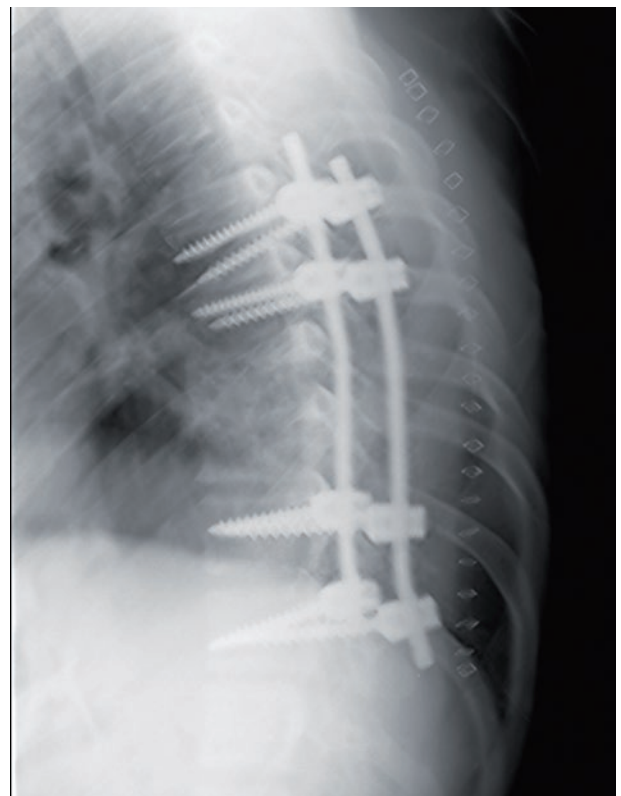

Figure 4.

COMMENTS

The interest of the case lies in the unspecific and latent clinical presentation which never included fever or toxic syndrome in spite of the remarkable involvement that the images depict.

CORRESPONDENCE

Dr. Rafael A. Guerrero
Área Sanitaria
rguerrero@gencat.cat

BIBLIOGRAPHICAL REFERENCES

1. López-Sánchez MC, Calvo G, Vázquez-Rodríguez VTR, Espondilodiscitis tuberculosa con tumoración lumbar. *Reumatol Clin.* 2012; 8(5): 292-293.
2. Belzunegui J. Espondilodiscitis infecciosa. *Reumatol Clin.* 2008; 4 Supl: 313-317.
3. García-Lechma JM, Julve R, Alcalá L, Ruiz-Serrano MJ, Muñoz P. Espondilodiscitis tuberculosa o enfermedad de Pott: experiencia en un hospital general. *Enferm Infecc Microbiol Clin* 2002; 20(1): 5-9.